

# ABERRANT CRYPT FOCI (ACF) IN DMH REACTIVATED RAT MODEL OF COLITIS

Inflammatory bowel disease (IBD), in its most common form of Crohn's disease and ulcerative colitis (UC), is characterized by presenting alternative phases of activity and quiescence that causes the intestine to become inflamed and bleed. Patients with IBD can develop dysplasia and colorectal cancer after many years.

**Purpose:** To create an IBD-cancer rat model to investigate histological association with the disease; and to look for the early signs of cancer during the transition from inflammation to dysplasia, such as aberrant crypt foci (ACF).

**Methods:** Four groups of Sprague-Dawley rats were used. Group 1 received prolonged reactivated colitis (a single intracolonic dose of trinitrobenzene sulfonic acid [TNBS] was followed six weeks later by "reactivation" with intravenous TNBS via a tail vein for three days). TNBS was administered twice a week afterwards. Group 2 received reactivated-DMH: For induction of cancer, the rats received a subcutaneous injection of 1,2-dimethylhydrazine (DMH) once a week following the reactivation. Group 3 rats received Control-DMH: Control rats were induced then reactivated using sterile saline, and received DMH; Group 4—Normal: normal controls received no treatment. Rats from each group were sacrificed at 5, 10 and 15 weeks after the first reactivation or injection of DMH. Segments of colon were analyzed by macroscopic analysis, and histological procedures.

**Results:** We expected to find increased numbers of ACF and damage in the DMH and TNBS animals compared to controls. It is possible that such markers could be used to predict the transition from inflammation to the early stages of cancer. These parameters can be related with genetic changes in future studies.

Student Researchers: Christine Santana; Cariluz Santiago  
Mentor: Caroline B. Appleyard, PhD

## INTRODUCTION

Colorectal cancer (CRC) is the second leading cause of cancer-related deaths in the United States. Inflammatory bowel disease (IBD), in the forms of ulcerative colitis and Crohn's disease, is a condition that can cause the intestine to become inflamed and to bleed. The cause of the disease is still unknown. Research has shown that patients with IBD, especially ulcerative colitis, have an increased risk for dysplasia and progression to CRC after several years. The aims of this study were: (1) to create an IBD-cancer rat model to investigate histological association with the disease; (2) to look for the early signs of cancer during the transition from inflammation to dysplasia, such as aberrant crypt foci (ACF). By producing an animal model of colitis-associated CRC, we expected to see an increase in the ACF in the tissues of the experimental rat models. Furthermore, we

wanted to find better markers that will allow us to diagnose the disease more precisely and earlier.

## METHODS

Male Sprague Dawley rats (~200g) were divided into 4 groups as described below ( $N=4$ ) and in Figure 1.

*Normal.* Normal control rats received no treatment.

*Control-DMH.* These rats received 0.5ml of sterile saline intracolonic, then 6 weeks later were 'reactivated' by administering intravenously via a tail vein 0.1ml/kg of sterile saline for three days. One week later the animals received dimethylhydrazine (DMH; 20mg/kg) subcutaneously once a week.

*Prolonged Reactivated Colitis.* A single intracolonic dose of trinitrobenzene sulfonic acid (TNBS; 30mg in 0.5ml of 50% ethanol) was followed six weeks later with intravenous injections of

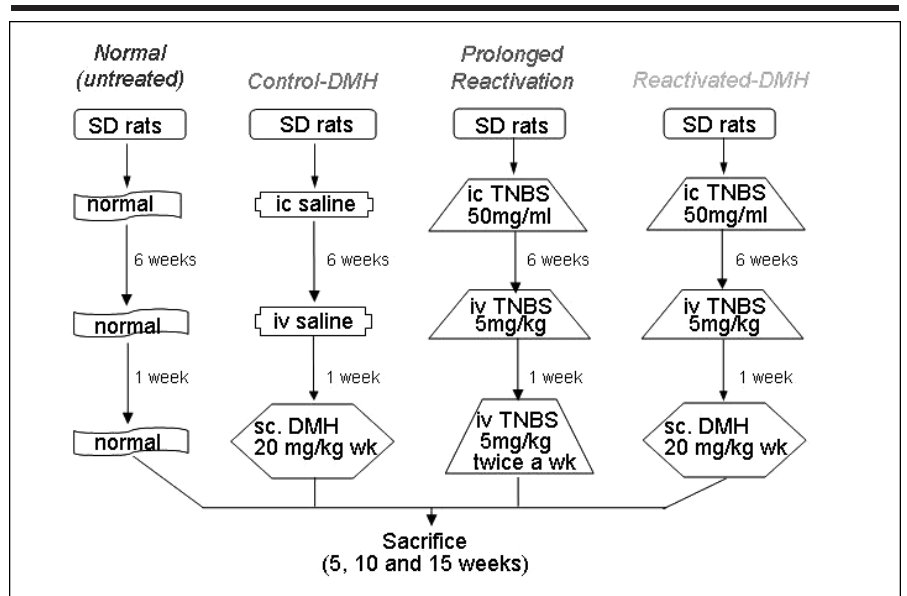
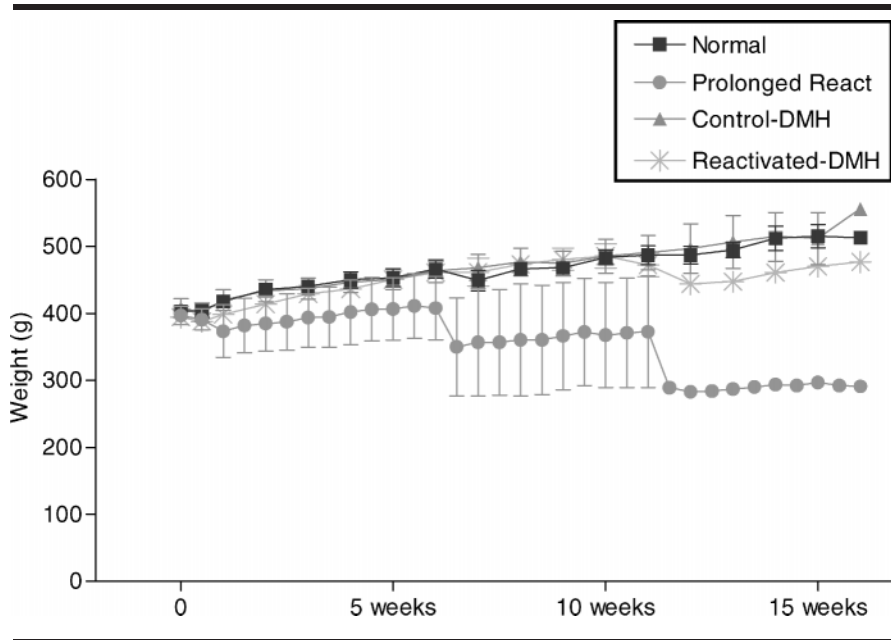


Fig 1. Steps taken with each of the four study groups

From the Physiology Department, Ponce School of Medicine; Ponce, Puerto Rico.



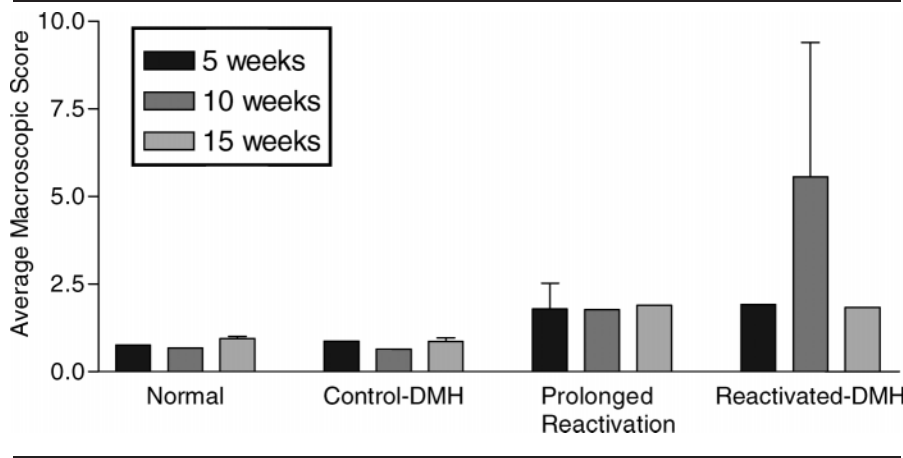
**Fig 2. Effect of reactivation and carcinogen treatment on weight. The weight of the Prolonged Reactivation group decreased in comparison to the other groups. In the Reactivated-DMH group a slight increase in weight loss was also observed in comparison to the Normal and Control-DMH groups; the latter groups gained weight normally**

TNBS (5mg/kg) for three days to produce a “reactivation” of the inflammation. One week later, TNBS (5mg/kg) was administered twice a week to mimic chronic colitis.

*Reactivated-DMH.* The animals received the same treatment of induction

and reactivation with TNBS as outlined for the Prolonged Reactivated Group, then one week later a subcutaneous injection of DMH (20mg/kg) was administered once a week for induction of cancer.

Rats from each group were sacrificed



**Fig 3. Effect of reactivation and carcinogen treatment on macroscopic damage. The average macroscopic scores in Normal and Control-DMH groups were very similar. A higher macroscopic score was observed in the Prolonged Reactivation group, which was highest in the Reactivated-DMH group**

at 5, 10 and 15 weeks after the first reactivation, or injection of DMH. An abdominal incision was performed; the colon was removed, opened longitudinally and scored for macroscopic damage using a previously published scoring system. The colon was divided into three equal parts: proximal, mid and distal. It was prepared for histology using the Swiss role technique. The tissues were processed for histological analysis using standard techniques. Sections were cut at 4µM and stained with Hematoxylin and Eosin for quantification of microscopic damage, or 0.2% Methylene Blue to look for ACF and presence of dysplasia.

## RESULTS

A decrease in weight, and an increase in total macroscopic damage score were observed in the experimental groups compared to controls (Figures 2 and 3).

When the tissue sections were examined microscopically, inflammatory signs were present in all the groups, with a higher degree of inflammation in the distal colon. ACF were found in the experimental groups after 15 weeks of treatment. Dysplasia was found in Prolonged Reactivated and Reactivated-DMH groups after 5 and 15 weeks of treatment.

## CONCLUSION

In conclusion, this new model of colitis-associated CRC may offer the potential to study the transition from inflammation to dysplasia to cancer, and could be used to identify new molecular markers in the future.

## ACKNOWLEDGMENTS

This study was supported in part by SO6GM08239, RR03050 and the NIDDK/CDU National High School Student Summer Research Program. Many thanks to Dr. Angel Isidro for his pathology expertise.